

Treatment of Low Back Pain in a Patient with Paget Disease of the Bone

Connie Bruno, M.D., Moshe Chinn, M.D., Paragi Rana, M.D.

Beth Israel Deaconess
Medical Center



Department of Anesthesia & Pain Medicine

Beth Israel Deaconess Medical Center, Harvard Medical School Boston, MA

Beth Israel Lahey Health

Background

The etiology of low back pain may be nonspecific or multifactorial, and it can sometimes be difficult or impossible to discern a specific cause. As such, it may be challenging to plan diagnostic studies or make appropriate treatment decisions. Conventional treatment algorithms are designed to first rule out life-threatening sources of pain such as cancer, infections, or cauda equina syndrome, by screening for red flags. Subsequently, common pain generators are evaluated using thorough history taking and physical exam, with imaging studies ordered when applicable. This case report acts as a reminder to search beyond the basic interventional treatment options at times, as a patient's pain may be multidisciplinary in nature.

The most common cause of bone disease is osteoporosis. Paget disease of bone is the second leading cause of bone disease. Paget disease is a bone remodeling disorder with increased osteoclastic bone resorption and compensatory rapid osteoblastic bone formation. It is usually an incidental finding because most patients are asymptomatic. Later in the clinical course, however, a deep bone ache can trouble patients. In some cases, fissure fractures, joint deformity, or malignancies may develop.

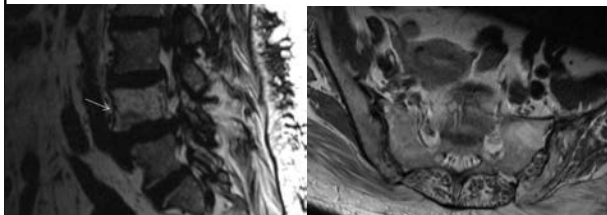
Methods/Case

This is a case report about an 84-year-old female with history of hypertension, diabetes, chronic kidney disease. She also had a possible diagnosis of Paget disease and had previously received yearly infusions at an outside hospital over 10 years prior to the evaluation. She presented with a four-month history of sharp, aching, 4-8/10 constant low back pain worse over the left buttock without radiation. The pain was exacerbated by walking, laying down at night, getting up after sitting for a long period. The pain was alleviated by OTC topical pain-relieving cream.

On exam, the patient had difficulty standing up straight. She ambulated with a walker. She was tender to palpation only over the left piriformis muscle. Patrick's test was negative bilaterally.

Results

- An x-ray of the pelvis, sacroiliac (SI) joint, and lumbar spine demonstrated a diffuse sclerotic
- appearance of the left hemipelvis and L4 vertebral body appeared expanded in size with a chronic L4 anterior inferior endplate fracture, consistent with Paget disease. She also had mild-to-moderate degenerative changes of the bilateral hip joints, most severe on the left and mild SI joint arthropathy. There were moderate degenerative changes of the lumbar spine predominantly at L4-L5 with disc space narrowing, anterior osteophytes, and facet joint arthropathy.
- She was referred to an endocrinologist, who discussed with the patient that treatment of Paget disease may not alleviate her pain. The patient had a normal alkaline phosphatase and bone scan did not show increased uptake. She received a trial of pamidronate IV infusion due to worsening pain.
- Her low back and buttock pain improved shortly after the infusion and she has had continued resolution for 6 months to date. She has had functional improvement in her ability to walk and stand for longer periods of time.



Conclusion

- Paget disease is a bone remodeling disorder that is usually an incidental finding because most patients are asymptomatic. It is diagnosed with a combination of radiographic evidence and elevated serum alkaline phosphatase level. It is not on the short list of our common low back pain differential, but nevertheless Paget disease is the second leading cause of bone disease. In our patient, the history of Paget disease was unclear and unable to be verified as it was remote in time. Although the bone scan and bone alkaline phosphatase did not verify the diagnosis, it was considered possible that the prior treatments reduced sensitivity and bisphosphonate infusion as given diagnostically and therapeutically. It is also known that there is a poor correlation between ALP value and presence of bone pain. Differential diagnosis for the patient also included myofascial piriformis muscle pain, referred facetogenic pain, SI joint pain, osteoarthritis of hip, and lumbar radiculopathy.
- Bisphosphonates, calcitonin, and denosumab have been reported to improve bone pain from Paget disease. Zoledronic acid is more likely to give bone pain relief than other bisphosphonates with decreased likelihood of pain relapse. Of note the Paget's Disease, Randomized Trial of Intensive versus Symptomatic Management (PRISM) and extension with zoledronic acid (PRISM-EZ) studies have revealed no benefit in bone pain between treatment groups at 2 years.

References

1. Charles JF, et al. Paget Disease of Bone. ASBMR Primer. 2019;9:713-720.
2. Ralston SH. Paget's Disease of Bone. NEJM. 2013;368:644-650.
3. Ralston SH, et al. Diagnosis and Management of Paget's Disease of Bone in Adults: A Clinical Guideline. JBMR. 2019;34:579-604.
4. Urits I. Low Back Pain, a Comprehensive Review: Pathophysiology, Diagnosis, and Treatment. CPHR. 2019;23:23.
5. Whyte, MP. Paget's Disease of Bone. NEJM. 2006;355:593-600.