



Brachioradial pruritus in a 52-year-old woman: A case report

Amnon A. Berger^a, Ivan Urits^a, Vwaire Orhurhu^b, Omar Viswanath^{c,d,e}, Jamal Hasoon^{a,*}

^a Beth Israel Deaconess Medical Center, Department of Anesthesia, Critical Care, and Pain Medicine, Harvard Medical School, Boston, MA, United States

^b Massachusetts General Hospital, Department of Anesthesia, Critical Care, and Pain Medicine, Harvard Medical School, Boston, MA, United States

^c Valley Anesthesiology and Pain Consultants, Envision Physician Services, Phoenix, AZ, United States

^d University of Arizona College of Medicine – Phoenix, Department of Anesthesiology, Phoenix, AZ, United States

^e Creighton University School of Medicine, Department of Anesthesiology, Omaha, NE, United States

ARTICLE INFO

Article history:

Received 2 October 2019

Received in revised form 20 October 2019

Accepted 28 October 2019

Keywords:

Brachioradial pruritus

Pruritus

Pain

ABSTRACT

Brachioradial pruritus is a specific subtype of neuropathic pruritus that commonly presents in women. This condition is a type of neurological itch that mostly involves the dorsal forearm. It is more common in fair-skinned females, is exacerbated by exposure to bright sunlight or ultraviolet radiation (UVR), and is associated with degenerative changes in the cervical spine. Diagnosis is difficult, and is usually delayed for 2–3 years. We describe a patient who suffered brachioradial pruritus for many years and was misdiagnosed by multiple specialists until she presented to our pain clinic. The patient had undergone invasive diagnostic testing by previous specialists but this had not led to diagnosis. After a thorough history and exam, the diagnosis of brachioradial pruritus was considered and the patient was treated with anticonvulsant medications, as these have been shown to be effective in this condition. This case is of interest to all physicians treating female patients as consideration of this diagnosis can avoid unnecessary invasive diagnostic testing.

© 2019 The Authors. Published by Elsevier B.V. This is an open access article under the CC BY-NC-ND license (<http://creativecommons.org/licenses/by-nc-nd/4.0/>).

1. Introduction

Pruritus is a common symptom, often caused by various skin conditions. However, it can also be a symptom of many other conditions, including rheumatic, endocrine, renal, hepatic, infectious, malignant and iatrogenic, as well as neuropathic, also referred to as neuropathic itch. Brachioradial pruritus (BP) is a specific subtype of neuropathic pruritus, which also includes notalgia parasthetica, postherpetic neuralgia, and multiple sclerosis. BP presents mostly as a dorsal forearm itch. It is more common in fair-skinned females, with some studies suggesting that more than 70% of cases occur in women [1,2]. The condition is often exacerbated by exposure to bright sunlight or ultraviolet radiation (UVR). Diagnosis is difficult, and is usually delayed for 2–3 years, but a combination of C5–C6 dorsolateral arm involvement (bilateral in 75% of cases), spinal abnormality and radiculopathy at these levels is highly suggestive. However, it is unclear whether cervical radiculopathy is at fault or is just a confounding factor, and the absence of either radiculopathy or exacerbation by UVR exposure does not preclude the diagnosis. The ice pack sign is considered pathognomonic for diagnosis and includes alleviation of pruritus when an ice-pack is applied to the

involved region and a return of symptoms when the ice-pack is removed [3]. We describe a patient who suffered brachioradial pruritus for many years and was misdiagnosed by multiple specialists until she presented to our pain clinic.

2. Case presentation

The patient was a 52-year-old woman who presented for evaluation of severe pruritus localized over her biceps and dorsal forearms. The patient had been suffering from this condition intermittently for 10 years but the symptoms had been worsening over the past year. She had initially been evaluated by her obstetrician during a routine well-woman exam. Her obstetrician suggested she see her primary care provider, who referred her to a neurologist and dermatologist for this issue. Through her many physician appointments, she had tried a variety of topical creams, including lidocaine and capsaicin, as well as medications such as diphenhydramine for assistance with the pruritus, but she had received no benefit. Skin biopsies had not led to diagnosis. The patient finally presented to our pain clinic for further assistance with her condition (Figs. 1 and 2).

Along with the history provided above, the patient reported that she routinely enjoyed sunbathing and occasionally used UV tanning beds. Additionally, she had a longstanding history of cervicgia and neck pain with cervical radiculopathy. A recent cervical magnetic

* Corresponding author.

E-mail address: jhasoon@bidmc.harvard.edu (J. Hasoon).

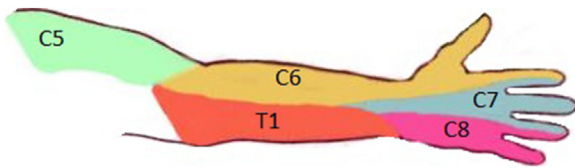


Fig. 1. Diagram demonstrating cervical dermatomes.

resonance scan had shown diffuse degenerative disease from C3 to C6. Upon further questioning the patient said she would occasionally place ice over her arms to help alleviate the symptoms when they were severe, though it would only replace the pruritus with feeling of coldness and numbness. The patient also demonstrated a positive “ice pack” sign in clinic.

Given this information, the patient was diagnosed with brachioradial pruritus and trialed on gabapentin. She was slowly titrated up on this medication over several weeks until she reached a steady

state. Initially the patient felt moderately sedated when starting the medication and would primarily take the medication before bed-time provided above, the patient reported that she routinely enjoyed sunbathing and occasionally used UV tanning beds. Additionally, she had a longstanding history of cervicgia and neck pain with cervical radiculopathy. A recent cervical magnetic resonance scan had shown diffuse degenerative disease from C3 to C6. Upon further questioning the patient said she would occasionally place ice over her arms to help alleviate the symptoms when they were severe, though it would only replace the pruritus with feeling of coldness and numbness. The patient also demonstrated a positive “ice pack” sign in clinic.

Given this information, the patient was diagnosed with brachioradial pruritus and trialed on gabapentin. She was slowly titrated up on this medication over several weeks until she reached a steady state. Initially the patient felt moderately sedated when starting the medication and would primarily take the medication before bed-time so it would not interfere with her daily routine. The patient

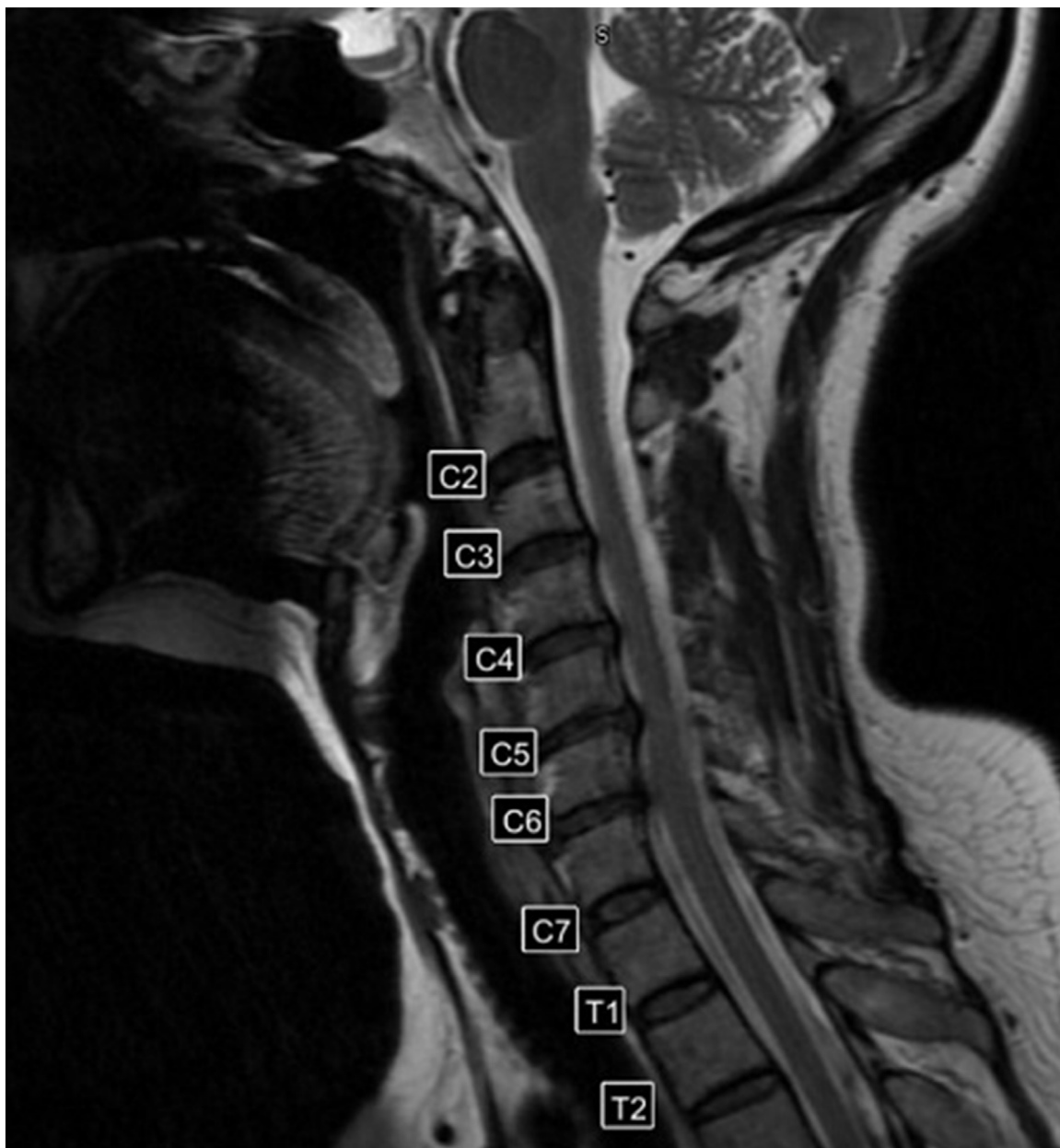

Fig. 2. Magnetic resonance scan of the cervical spine demonstrating diffuse degenerative changes.

eventually reported that she was able to tolerate the medication and slowly increased the dosage to 400 mg three times a day. She was soon able to tolerate the medication with no side-effects and slowly started noticing improvements in her symptoms. After several weeks of being on the medication she reported significant improvement in her symptoms and reported minimal side-effects.

3. Discussion

The etiology is not completely understood, though different series have shown increased rates of concomitant cervical spine disease at C5-C8 levels in patients with BP. A recent study of 120 patients with different types of chronic pruritus (CP), including BP, suggested a reduced descending inhibitory system in CP and sensitization of cutaneous mechano- and heat-sensitive C-fibers [4]. However, the mechanism of pruritus in these patients is still elusive.

For cases where surgical decompression is not indicated, treatment is usually based on avoidance of UVR exposure as well as medication, though it is unclear what medical regimen is most effective. Some studies have found anti-depressants and anti-convulsants to be beneficial. Amitriptyline, fluoxetine and doxepin have been shown to be helpful. Gabapentin was also helpful and was the drug most prescribed when pruritus was described as most intense. Importantly, there is evidence that shorter treatment is associated with a lower response rate, suggesting the need for chronic medical treatment of BP [5].

Topical antihistamines and capsaicin have not been effective. In a recent case report, one patient's refractory BP had a good response to topical amitriptyline and ketamine, after systemic therapy had failed, including with gabapentin and cyclobenzaprine. Of note, however, is that the patient had not been treated with systemic anti-depressants prior to this. This does present an interesting approach, sparing the patient systemic medical treatment [6]. However, given the overall safety of antidepressants and neuro-pathic agents, we believe physicians should consider this approach if more conventional treatments have failed.

Another approach to treatment targets the radiculopathy associated with BP with interventional injections. A recent case series described the use of computer tomography (CT)-guided cervical nerve root blocks for treatment of BP. Of the three patients who underwent trans-foraminal epidural steroid injections (TFESI) of the cervical spine under CT guidance, immediate positive results were obtained in two. The third patient required repeated injections with the addition of mexiletine for relief [7]. This interventional pain procedure may be considered after more conservative therapies have been trialed.

4. Conclusion

Brachioradial pruritus can be a challenging condition to diagnose and may present to a variety of subspecialists. The diagnosis should be entertained in female patients in their 40s or 50s with a history of UVR exposure, degenerative changes in their cervical

spine, and symptoms of pruritus in their dorsal forearms. The "ice pack" test can be easily applied in the clinic and may aid diagnosis. Our case demonstrates that these patients can often be misdiagnosed and can have unnecessary invasive procedures such as biopsies with no relief in symptoms. Physicians should consider this diagnosis and can instead try patients on medications such as antidepressants or anticonvulsants as a conservative measure before investigating more invasive options.

Contributors

Amnon A. Berger contributed to the literature review and drafted the manuscript.

Ivan Urits contributed to revision of the manuscript.

Vwaire Orhurhu contributed to revision of the manuscript.

Omar Viswanath contributed to revision of the manuscript.

Jamal Hasoon contributed to the literature review and revision of the manuscript.

Conflict of interest

The authors declare that they have no conflict of interest regarding the publication of this case report.

Funding

No funding from an external source supported the publication of this case report.

Patient consent

Obtained.

Provenance and peer review

This case report was peer reviewed.

References

- [1] S.A. Mirzoyev, M.D.P. Davis, Brachioradial pruritus: mayo clinic experience over the past decade, *Br. J. Dermatol.* 169 (5) (2013) 1007–1015.
- [2] Ana Cecilia Versiani Duarte Pinto, et al., Clinical, epidemiological and therapeutic profile of patients with brachioradial pruritus in a reference service in dermatology, *An. Bras. Dermatol.* 91 (4) (2016) 549–551.
- [3] Jeffrey D. Bernhard, Jeremy S. Bordeaux, Medical pearl: the ice-pack sign in brachioradial pruritus, *J. Am. Acad. Dermatol.* 52 (6) (2005) 1073.
- [4] Esther M. Pogatzki-Zahn, et al., Peripheral sensitisation and loss of descending inhibition is a hallmark of chronic pruritus, *J. Invest. Dermatol.* 19 (2019) 31851–31852.
- [5] Patrick Alexander Wachholz, et al., Impact of drug therapy on brachioradial pruritus, *An. Bras. Dermatol.* 92 (2) (2017) 281–282.
- [6] Maja Magazin, Robert P. Daze, Nicholas Okeson, Treatment refractory brachioradial pruritus treated with topical amitriptyline and ketamine, *Cureus* 11 (7) (2019).
- [7] Brent D. Weinberg, et al., Brachioradial pruritus treated with computed tomography-guided cervical nerve root block: a case series, *JAAD Case Rep.* 4 (7) (2018) 640–644.